

National consensus for management of patients with cervical intraepithelial neoplasia caused by human papillomavirus infection

Working group:

- **Zaporozhan V. M.** – moderator, President of the Association of obstetricians-gynecologists of Ukraine, MD, Professor, Academician of NAMS of Ukraine, Vice-President of NAMS of Ukraine, rector of Odessa National Medical University;
- **Kaminskiy V. V.** – moderator, MD, professor, corresponding member of NAMS of Ukraine, Head of the Department of Obstetrics, Gynecology and Reproductology, NMAPE named after P.L. Shupyk, Chief Freelance Specialist of the Ministry of Health of Ukraine in the field of Obstetrics and Gynecology, Chief obstetrician-gynecologist of the Ministry of Health of Ukraine;
- **Svintsitskiy V. S.** – moderator, MD, National Cancer Institute (Kyiv); Chief Freelance Specialist of the Ministry of Health of Ukraine in the field of "Gynecologic Oncology";
- **Beniuk V. O.** (Kyiv);
- **Goncharenko V. M.** (Kyiv);
- **Kovalchuk I. V.** (Kyiv);
- **Marichereda V. G.** (Odesa);
- **Potapov V. A.** (Dnipro);
- **Revenko O. A.** (Kyiv);
- **Suslikova L. V.** (Kyiv);
- **Shalko N. N.** (Kyiv);
- **Voloshyna N. M.** (Zaporizhzhia);
- **Kyshakevych I. T.** (Ivano-Frankivsk);
- **Kornatska A. G.** (Kyiv);
- **Nahorna V. F.** (Odesa);
- **Pyrohova VI** (Lviv);
- **Shumenko V. V.** (Kyiv);
- **Chayka K. V.** (Kyiv);
- **Shcherbina M.O.** (Kharkiv)

Pathological processes of the cervix uteri (CU) are of particular importance in the clinical practice of obstetricians; gynecologists, and in the general aspect of health. Their frequency is extremely high and has no tendency to decrease. Early detection and adequate treatment of background processes and pre-malignant condition of CU can prevent the ocervical cancerence of cervical cancer. In view of this, the problem of early diagnosis and treatment of pathological conditions of CU in regard to reproductive health of patients is of particular importance, as the lack of the disease symptoms leads to its progression. It is especially challenging issue in the modern emancipated world, when men often give way to women in providing family and bringing up children.

Numerous studies of morphologists, oncologists, gynecologists and immunologists suggest that the risk factors for cervical cancer include DNA-containing viruses such as human papilloma virus (HPV) which are causal factor for this pathology.

Non-integrated form of infection is characterized by the production of intact viral particles, and that's when human papillomavirus infection (HPV-infection) is asymptomatic and highly pathogenic.

Presently, it has been proved that the viral infection may remain latent for several years, while its presence increases the risk of cervical cancer on average 300 times at the persistence of strains of high carcinogenic risk [4, 5, 7].

HPV is diagnosed in 10% of patients with background CU processes (diseases). Therefore, the issue of HPV infection deserves special attention, due to the presence of a viral factor the patients are regarded as being in a high risk group for the cervical cancer development. According to numerous literature data, HPV infection and cancer are combined in 50-84% of cases.

HPV infection can be attributed to diseases that affect the demographic parameter of the country, because HPV infection is a sexually transmitted infection. In the case of pregnancy, due to the fact of immunity change, latent HPV infection switches into an active state

and accelerates the neoplastic transformation of cervical epithelium. Infection during pregnancy and childbirth is also possible. As a rule, young girls and men in the age of 20-30 years are affected, as they come to the oncologist in long-standing condition, as the malignant form occurs slowly and almost imperceptibly for the patient.

This document provides basic information regarding the symptoms of HPV infection, and sets out guidelines for the management of patients with the aim of preventing cancer in women who are diagnosed with this infection.

Definition

HPV infection is a process caused by human papilloma virus (HPV – Human papiloma virus), which is able to replicate in the human body.

As other representatives of papillomaviruses, it has the property to infect skin or mucosa keratinocytes. Most known HPV types cause diseases with symptomless course, but some of them cause frequent formation of papillomas, keratoses, condylomas, and malignant neoplasms.

Epidemiology

CU diseases occupy a leading place in structure of the reproductive system diseases; they are found in 15-20% of women of reproductive age, and 5-9% of women of menopausal age. Even cases of benign background processes make, according to various sources, 35-80% of the whole number of references for gynecological care.

Every year about half a million women with cervical cancer are registered worldwide, and up to 270 thousand of them die during the first year after establishing diagnosis. Cervical cancer is ranked second in the structure of gynecological oncological diseases in the countries of the European Union (EU). About 33,000 new cases of cervical cancer, and up to 15,000 deaths by this disease are registered every year in the EU [1]. The incidence of cervical cancer in Ukraine is much higher than the global statistics (11.04 vs 7.94 per 100 thou-

sand women), and mortality rates exceed the world almost 2 times (or 4.9 versus 3.2 per 100 thousand women, respectively).

As for the prevalence of HPV infection, today it is the most common worldwide, with the global score 11.7%. According to epidemiological studies, at least 95% of squamous cell cervical cancer cases contain HPV DNA. On a global scale about 630 million people are infected with HPV [8, 10, 12]. It is important to note that the peak of HPV-infection falls into the age group of 20-25 years, that is, the period of reproductive and sexual activity of women. Upon this, the following 5 highly oncogenic HPV genotypes are most frequently detected: HPV-16 (47%), HPV-18 (29%), HPV-52 (9%), HPV 31 (8%) and HPV-58 (7%) [2].

This infection is considered as one of the main causes of precancer and cervical cancer. Epidemiological research establishing a connection between HPV infection and cervical cancer, was published in 1990-ies [2, 6, 7, 9]. According to the WHO (1986), the development of squamous and adenoid cervical cancer is closely associated with promiscuous sexual behaviour accompanied by frequent changes of sexual partners and exposure to sexually transmitted infectious agents.

Etiology

It is proved that the main cause of cervical cancer (72-90% of cases) is persistent HPV infection. The causative agent of HPV infection is DNA containing virus which belongs to genus Alpha papillomavirus of Papillomaviridae family, the virus affects basal membranes of mucosa.

HPV cells are distinguished by the genetic sequence of the outer capsid protein L1. The genital tract is infected by more than 30 HPV strains. HPV types of high, potentially high- and low-oncogenic risk are known today. HPV of low-risk include the following types: 6, 11, 34, 35, 40, 42, 43, 44, 54, 55, 61, 62, 70, 71, 74. HPV of potentially high risk the following types: 26, 53, 66. HPV of high risk include the following types: 16, 18, 31, 33, 45, 51, 52, 58, 59, and 39 [1, 3, 4].

One of the reasons leading to the development of CU pathologies are induced abortions that lead to trauma, neuroendocrine disorders and infections indirectly affecting immature (incomplete) CU epithelium. CU pathology can be also caused by inflammatory diseases of female genital organs; it is one of the most pressing health problem that significantly affects the health of millions of women of childbearing age. Incidence of HPV infection depends largely on early sexual debut, number of sexual partners, long-term use of oral contraceptives, infertility, obesity, smoking.

A woman who smokes belongs to the group of increased risk for the development of precancer and cervical cancer. Researchers G. I. Rzepka et al (1993), S. E. Waggoner et al. (1994) founded that nicotine is accumulated in cervical mucus in proportion to its blood concentration. Its normal concentrations do not cause pathological effects but there is a selective mitogenic effect of nicotine on ectocervix cells, and especially when they are defeated by HPV.

There is evidence that every third sexually active woman has various forms of clinical manifestations of HPV lesions. Most often (95% of cases), HPV is localized in the CU transition zone in which neoplasia of the CU epithelium occurs. HPV affects pathological proliferation in columnar epithelium. Highly oncogenic HPV-infection types are the main etiopathogenetic cause for the development of CU neoplasia. HPV's integrate into the genome of basal epithelial cells and compromise their genetic stability, which leads to cervical cancer.

Processes contributing to the restoration of CU zones and the formation and growth of reserve epithelium cells of depend on many factors. The CU condition can be affected both directly and indirectly by the following factors: age, inflammatory processes and their nature, infections, hormonal and immune status of the body. The factors that

increase the risk of CU pathologies include disorders of hormonal and immune status, menstrual cycle, abortions, inflammatory processes of genital organs, etc., especially in the setting of HPV infection.

Diagnosis

Over the 1st years, the problem of diagnosis and treatment of precancerous and neoplastic CU diseases associated with HPV has acquired special urgency due to a spur increase in the incidence of cervical cancer, high oncogene potential of the virus, ineffectiveness of traditional therapy and the lack of specific antiviral therapy.

A distinguishing feature of HPV infection is the fact that the virus is not detected in the blood due to its epitheliophilicity, and antibody response of immune system is observed far not at all affected persons, due to the inability of the body to provide a long-term immunity at a very low level of antibodies [1, 3-5]. As a result, HPV DNA is preserved in the CU epithelium for a long time causing an abnormal transformation of epithelial cells. Consequently, up to 88% of patients with neoplasia of CU epithelium have cytological signs of HPV infection, and infection of cells is located in the transformation zone in 80,2% of cases [2, 3].

The philosophy of cervical screening is based on the following "three pillars": cytology with HPV testing, colposcopy, and histology. PAP test is often used in various countries around the world. This is the most successful and cheapest test in the history of medicine that can proactively prevent all types of cervical cancer subject to its correct implementation.

Screening for CU pathology is a way to prevent the development of cancer process through the detection and treatment of pathological changes in the CU epithelium in women who, if untreated, can develop invasive cervical cancer. A woman can be insured against cervical cancer subject to a timely detection of such changes and appropriate treatment together with explanation of the means of prevention and the need for regular medical supervision [15]. Unfortunately, up to the present moment cytological screening have been insufficiently used, because it remains opportunistic, that is, a survey upon request. When carried out systematically, screening helps prevent up to 80% of cases of cervical cancer, as it was proven in many countries of the European Union.

Instrumental method

Clinical signs of CU pathology are clearly defined in the course of pelvic exam by simple and extended colposcopy.

colposcopy allows a clinician to examine the genital tract (tissues) with 8 - 40-times magnification. The use of the test with 3% acetic acid allows to detect acetowhite epithelium (AWE). The presence of AWE is an important colposcopic test which is used in the latest International vginoscopic terminologies (Rio;where;Sheikh, 2011). Certain epithelial changes in the damaged zones of epithelium, that is, subclinical changes (lesions) that contain well-defined white spots, granular or smooth surface and vascular changes, help to find place for further cytological examination and biopsy.

Vginoscopy is an important method of in-depth diagnostics of pathological changes in the CU epithelium. In many countries, colposcopy is not used for cervical cancer screening. Special training and practical experience of a physician is required for avoiding errors in the diagnosis and treatment of CU pathological conditions.

In the course of visual diagnosis of CU pathology Schiller's Iodine test is also used, it consists in applying Lugol's iodine to the cervix. CU epithelial cells containing glycogen stain brown. In the cse of CU diseases, the amount of glycogen is reduced, and accordingly the absorption decreases. These zones are interpreted as Lugol-negative zones. When detected, it is necessary to conduct an in-depth examination such as colposcopy and HPV test, on therapeutic grounds. During the extended colposcopy, the condition of surface epithelium of CU and

vagina, as well as zones with pathological changes is studied.

The following changes in the colposcopic pattern indicate the presence of HPV-infection:

- 'acetowhite epithelium;
- pointed and flat condylomas;
- rimmed glands. Rims of acetowhite (metaplastic dysplastic) epithelium appear at the location of excretory ducts of the glands, which may be a sign of HPV persistence. In this case, a compulsory targeted biopsy for histological examination shall be carried out, in order it to exclude the presence of cancer;
- atypical vessels and atypical transformation zones;
- mosaic;
- Punctuation (according to modern terminology, 2011);
- keratosis (leukoplakia);
- iodine-negative zones of epithelium.

Pathologically changed zone shall be sampled for cytological examination, and further – on therapeutic grounds – for histological examination.

International classification of colposcopic terms adopted at the VII World Congress for Cervical Pathology and Colposcopy (Rome, 1990)

- I. Normal colposcopic findings
 1. Original squamous epithelium.
 2. Columnar epithelium.
 3. Normal transformation zone.
- II. Abnormal colposcopic findings:
 - A. Within the transformation zone:
 1. Acetowhite epithelium:
 - a) Flat;
 - b) Micropapillary or microconvoluted.
 2. Punctuation.
 3. Mosaic.
 4. Keratosis (leukoplakia);
 5. Iodine-negative epithelium.
 6. Atypical vessels.
 - B. Outside the transformation zone (ectocervix, vagina).
 1. Acetowhite epithelium:
 - a) Flat;
 - b) Micropapillary or microconvoluted.
 2. Punctuation.
 3. Mosaic.
 4. leukoplakia.
 5. Iodine-negative epithelium.
 6. Atypical vessels.
- III. Colposcopically suspect invasive carcinoma.
- IV. Unsatisfactory colposcopy:
 1. Squamocolumnar junction not visible.
 2. Severe inflammation or severe atrophy.
 3. Cervix not visible.
- V. Miscellaneous findings:
 1. Non-acetowhite micropapillary surface.
 2. Exophytic condyloma.
 3. Inflammation.

4. Atrophy.
5. Ulcer.
6. Other.

Colposcopic classification of pathological processes in the cervix (Kokhaneych E.V. Ganina K. V. et al. 1967,1997)

- I. Benign (background) pathological processes:
 1. Ectopia of columnar epithelium:
 - a) Dyshormonal;
 - b) Post-traumatic.
 2. Benign transformation zone (zone of benign metaplasia):
 - a) uncompleted transformation zone;
 - b) completed transformation zone.
 3. Inflammatory processes of the cervix:
 - a) exocervicitis;
 - b) endocervicitis.
 4. True erosion.
 5. Benign polipous lesions.
 6. Cervical endometriosis.
- II. Precancerous cervical conditions:
 1. Simple leukoplakia.
 2. Dysplasia charts:
 - a) multilayered squamous epithelium;
 - b) metaplastic columnar epithelium.
 3. Papillary dysplasia zone:
 - a) multilayered squamous epithelium;
 - b) metaplastic columnar epithelium.
 4. Precancer transformation zone.
 5. Condylomas.
 6. Precancerous polyps.
- III. Preclinical cervical cancer:
 1. Proliferative leukoplakia.
 2. Atypical epithelium charts.
 3. Papillary atypical epithelium zone.
 4. Atypical transformation zone.
 5. Atypical vascularization zone.
- IV. Clinically apparent cancer:
 1. Exophytic form.
 2. Endophytic form.
 3. Combined form.

Colposcopic classification of Colposcopy terminology (IFCPC Rio de Janeiro, 2011)

- I. General provisions:
 1. Adequate/inadequate for the reason ... (i.e.: cervix obscured by inflammation, bleeding, scar, etc.).
 2. Squamo-columnar Junction visibility (completely visible, partially visible, not visible).
 3. Transformation zone types 1,2,3.
- II. Normal colposcopic findings:
 1. Original squamous epithelium (Mature, atrophic).
 2. Columnar epithelium (ectopy).
 3. Metaplastic squamous epithelium (nabothian cysts, crypt (gland) openings).

4. Deciduous in pregnancy.
- III. Abnormal colposcopic findings:
 1. General principles:
 - a) location of the lesion (Inside or outside the T-zone, Location of the lesion by clock position);
 - b) Size of the lesion (Size of the lesion in percentage of cervix).
 2. Grade 1 (Minor):
 - a) Thin aceto-white epithelium. Irregular, geographic border:
 - Fine mosaic;
 - Fine punctation.
 3. Grade 2 (Major):
 - a) Dense aceto-white epithelium with sharp borders;
 - b) a quick whitening;
 - c) Cuffed crypt (gland)
 - openings with aceto-white dense rims;
 - Coarse mosaic;
 - Coarse punctation;
 - Inner border sign, contours are outside of aceto-white area;
 - Ridge sign (ridges).
 4. Non specific finding:
 - a) leukoplakia;
 - b) erosion;
 - c) Lugol's staining (Schiller's test):
 - iodine-positive (stained);
 - iodine-negative (non-stained).
- IV. Suspicious for invasion:
 1. Atypical vessels. Additional signs: Fragile vessels, Irregular surface, Exophytic lesion, Necrosis, Ulceration (necrotic) areas.
- V. Miscellaneous finding:
 1. Congenital transformation zone.
 2. Stenosis. Condylomas.
 3. Congenital anomaly.
 4. Polyps.
 5. Post treatment consequence.
 6. Inflammation.
 7. Endometriosis.

Laboratory diagnosis

The first stage of screening for CU pathology is cytological examination. This procedure can be performed by general practitioner or even a nurse after a special preparation and training. Not only the quality of the diagnosis, but even the health of the woman depends on the correct biopsy sampling for cytological examination. Material for cytological examination should be taken from the CU surface, transformation zone and cervical canal. This allows the cytologist to assess the CU epithelium and to identify intraepithelial lesions of various degrees of malignancy.

Father of cervical cytology is G. Papanicolaou, who published in 1928 the article "New cancer diagnosis". He described the test for the detection of cervical cancer at early stages. In 1943, together with Herbert Traut, he published a monograph "Diagnosis of endometrial cancer by the vaginal smear". The book describes the methodology of

cytological examinations by using the stain technique associated with the author's name until today: Papanicolaou staining. It became the basis for screening programs in the next decade in many countries of the world. The implementation of these programs helped to reduce the morbidity and mortality from cervical cancer by 50-80% (70) [12].

Screening for pathology of cervical cancer pathology is not a test for cancer. By using it, probable disorders or changes in cells can be detected that can cancerate, if not prevented. Most changes detected by using cervical cancer screening are successfully treatable. The quality of cytological sampling, and the accuracy of laboratory reports according to smear microscopy constitute an essential component of screening test.

However, widespread use of conventional cytology has some drawbacks, namely:

- high percentage of poor-quality smears, thus requiring re-sampling;
- difficulties in qualitative assessment of cell material (a small amount or an excess of cells, layering, mechanical cell damage, incorrect fixation, the presence of blood cells, elements of inflammation).

All this predetermines the probability of untimely detection of cells with precancerous changes in the presence of large background or incorrect assessment of the nature of the changes due to the layering of the cells and other factors. Diagnostic sensitivity of the cytological method makes averagely about 60%, which means that in 40% of cases the results do not correspond to the rate of existing changes (are false negative).

Thus, in 1996, in the United States, the technique of liquid-based cytology (LBC) was introduced for the first time. This method differs from the traditional one in that sampled cells of cervical epithelium are placed into a special liquid medium and sent to the laboratory, where the smear will be prepared with the help of special equipment, and then stained. Liquid-based cytology method allows to correct some of drawbacks of conventional cytology. This, in turn, improves the diagnostic sensitivity of cytological screening.

Distinctive features of Liquid-based Cytology method are as follows:

- the entire sample obtained from the cervix is kept;
- wet fixation in preservative liquid improves the clarity of cellular structures and eliminates the appearance of artefacts when dried in air;
- possibility of obtaining a fine representative monolayer specimen that allows to detect timely single cells with pre-cancerous changes, and demonstrate the need for an additional examination;
- possibility of preparing additional specimens (up to five), if the first one was unsatisfactory. The method allows to keep samples for a long period of time: for 4 weeks in a container and for 6 weeks in the refrigerator;
- the number of specimens not fit for the assessment is reduced;
- sensitivity to mild neoplasia is increased;
- specificity of general cytological method is increased;
- the sample can be used for carrying out auxiliary studies, such as detection of HPV infection, determination of proliferation markers P16/Ki67 and other markers.

Clinicians must take into account that the quality of cytological examinations as for the effectiveness of secondary prevention (regardless of the method used for the smear preparation) depends on the following:

- a) strict compliance with the rules of preparation of the patient for cytological screening;
- b) special aspects of obtaining valuable material [10].

The effectiveness of the PAP test depends on traditional preparation of the patient, quality of sampling by the gynecologist, correct slide technique, adequate and timely wet fixation, correct staining of specimens and correct interpretation of cell changes by a cytologist.

The most effective staining technique recognized worldwide is Papanicolaou test, since polychromatic stainings allow to stain structures of the cytoplasm and nucleus.

One of the factors that provide the effectiveness of cytological examinations in the framework of cervical screening is a referrals for tests including passport data of the patient, clinical diagnosis, date of the last menstrual period or the menopause duration, and performed treatment (hormone replacement therapy, oral contraceptives). All these data allow to adequately assess the character of changes of the cervical epithelium, and draw an objective cytological conclusion. In the laboratory, the cytologist shall primarily assess the full-value of the material. In accordance with the criteria of the smear fitting for the interpretation, they include the presence of 8000-12 000 cells of squamous epithelium for a conventional cytological examination, or 5000 cells for LBC examination. The availability of at least 10 cells of columnar and metaplastic epithelium is an essential condition. After the assessment of the specimen, the cytologist shall draw a cytological conclusion on the basis of cellular changes, according to the classifications approved [12].

Today, there are several classifications:

- The Bethesda system (TBS) is used for cytological examination by Papanicolaou test (CIN classification). The classification was adopted in 1988 in Bethesda (MD, USA). It was revised and partially amended in 2001, 2006, 2012. The last version was held in 2014 This classification is recommended worldwide as the best optimal system for the issuance of cytological conclusions. It defines a two-tier system of accounting for squamous and intraepithelial lesions (LSIL and HSIL), which reflect the biology of the changes taking place in the presence of HPV-infection: productive (episomal) one which corresponds to LSIL, and integrated one which corresponds to HSIL.
- for histological specimens: the WHO classification, the CIN classification.

As for today, according to main international recommendations in cytological screening, it is recommended to issue cytological conclusions in accordance with the Bethesda system (2014), which identified the following categories of changes:

- NILM (negative for intraepithelial lesion or malignancy).

For the assessment of **squamous cervical epithelium**:

- LSIL (low-grade squamous intraepithelial lesion);
- HSIL (high-grade squamous intraepithelial lesion);
- ASC-US (atypical squamous cells of undetermined significance);
- ASC-H (atypical squamous cells can not exclude HSIL);
- Squamous cell carcinoma.

For the assessment of **columnar cervical epithelium**:

- AGC favor neoplastic (atypical glandular cells, favour neoplastic);
- AGC-US (atypical glandular cells of undetermined significance);
- AIS (endocervical adenocarcinoma in situ);

- adenocarcinoma.

One of distinguishing features of this classification is defining the ASC-US/ASC-H categories for squamous epithelium and AGC-US/AGC favor neoplastic categories for glandular epithelium, which allows to suspect the presence of pre-cancerous conditions and demonstrate the need for an in-depth examination of the patient. Issuance of the conclusion of cytological examination in accordance with the TBS helps to standardise the presentation of cytological conclusions worldwide for the possibility of exchange of experience in the tactics of management of various types of pathology. Stratification of ASC-US/ASC-H categories for squamous epithelium and AGC-US/AGC favor neoplastic can improve the diagnostic sensitivity of cytological screening. As for today, cytological examination in many countries remains the primary method for cervical cancer screening.

The work of cytologist and gynecologist are united by classification. With the help of it, it becomes possible to show the image seen by the cytologist, and the gynecologist is able to determine further tactics of the patient management. According to the classification, the physician shall determine clinically meaningful information. In fact, information about the smear types is not all that the cytologist intends to transfer to the gynecologist. Classification must meet the current notions of neoplasia.

It is obvious that the terminology according to the Bethesda classification differs from accustomed conventional types such as: NILM, LSIL, HSIL, ASCUS, ASC-H, AGC. It should be noted that when using this classification it is not recommended to use LSIL to describe glandular epithelium. It should be noted that "columnar epithelium dysplasia" of mild moderate grade is not included in the Bethesda classification, only "severe dysplasia" is included (AGC).

It is also necessary to pay attention to neoplastic cellular changes, in particular squamous metaplasia being managed in a wrong way. If stained in a wrong way, they can be interpreted as keratosis.

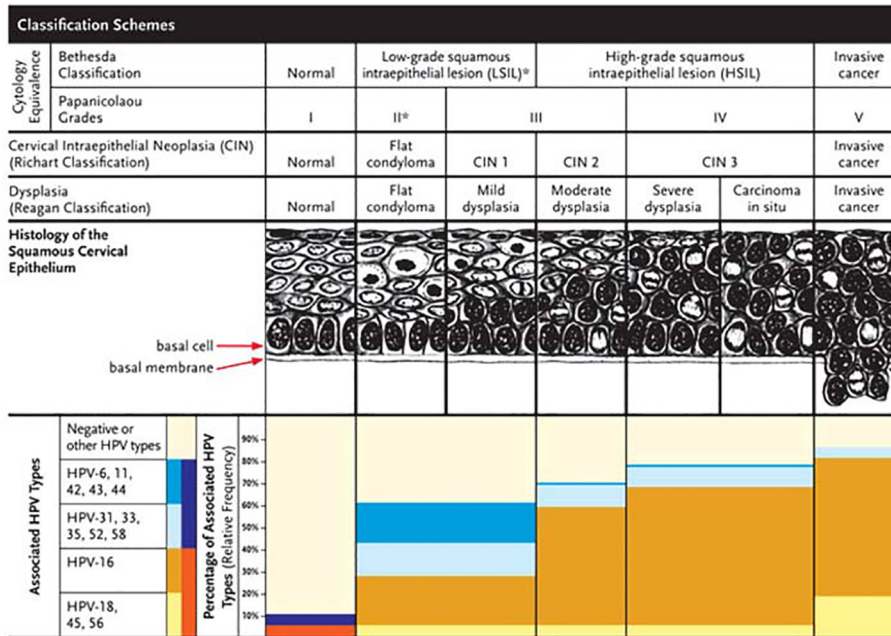
Hyperkeratosis, dyskeratosis, metaplasia, atrophic change - all of them are normal variants, although these changes do not exclude the HPV-infection.

It is important to consider that the pathology of the cells is divided into two subtypes: pathology of cells of (squamous) multi-layered squamous epithelium and pathology of cells of glandular epithelium. The pathology of the cells of glandular epithelium is responsible for an absolute discrepancy incongruity with the classification by type. As for today, an increase in the number of cases of the pathology of this epithelium and endocervical cancer is noted [13, 15].

Uncompleted transformation zone and glandular crypts of epithelium in exo - and endocervix are the most vulnerable to the penetration of HPV and the development of cervical glandular intraepithelial neoplasia (JING); it is a condition under which no CU exocervix pathology is detected, while with the help of colpocervicocopy and PAP-test glandular neoplasia and its most severe form - adenocarcinoma can be detected in endocervix [13].

Screening programmes in the USA and some EU countries include screening for HPV infection in women after the age of 30 years, due to the proven role of HPV infection in the development of cervical cancer (see Fig.). Inclusion of type-specific DNA test contributes to identifying not only cytological changes but also a group of women

with normal cytology at risk of cervical intraepithelial neoplasia. Some of HPV-infected patients show a process of spontaneous viral clearance, and in 10-15% (one of 10-30 women) of HPV-infected patients cytological atypia is diagnosed. However, the ability to HPV-viral clearance is mainly observed among young women under the age of 25 years. HPV persistence is more frequent (more common) after the age of 30 years. It should be taken into account that smoking and immunosuppressive therapy double the risk of cervical intraepithelial



neoplasia progression up to CINIII in HPV-positive women. That is why HPV testing formed the basis of the recent WHO recommendations for screening, diagnosis and treatment of cervical cancerous lesions.

According to TBS, cytological interpretation also includes pathogenic micro-organisms (Trichomonas; Candida fungi; shift in vaginal flora characteristic of bacterial vaginosis; actinomycetes, and cells characteristic of herpes simplex virus and cytomegalovirus). Special attention should be paid to viruses. The doctor should distinguish herpes simplex and cytomegalovirus viruses, or HPV.

Correspondence of different classifications

What shall a gynecologist know when HPV-infection is detected? This infection is characterized by a latent form without cytological signs. The virus manifests itself cytologically in the productive phase with a specific marker of koilocytosis.

During processing of large arrays of cytological test databases it was established that even in the case of ASCUS cancer in situ can be diagnosed in 2% of cases (CIS). In the case of LSIL, CIS can be observed in 10% of cases, and invasive cancer - in 0.2% of cases.

According to the recommendations of American colleagues, there is no need to apply colposcopy or biopsy in such cases, but at the same time there is no need to return to a routine screening of the patient. However, co-testing must be repeated after 6 and 12 months. If there an atypia or a HPV-positive result has been detected, a conventional examination such as colposcopy, biopsy and cervical curettage shall be conducted. In the cytology is unchanged, the patient shall be returned to routine screening.

According to recent WHO recommendations, screen and treat strategy shall be implemented. Screening begins with an HPV-test. If a woman is viruspositive, a visual examination shall be conducted. cryosurgery is recommended in the presence of acetowhite spot or iodine-negative area without biopsy and colposcopy . This is the expert WHO recommendation. Cryotherapy, and not a cone biopsy shall be carried out, as the latter causes a higher risk of bleeding and premature birth. However, experts indicate fewer recurrences of the disease just in the case of cone biopsy.

But is this recommendation appropriate for our conditions? For the implementation of screen and treat system it is necessary to take

a step back. The answer to these questions can be found in the same recommendations that claim that cytology, colposcopy, and biopsy with subsequent treatment (that is what we are accustomed to) are appropriate methods and have the right to life, if they have already been developed. It should be clearly understood that this respectable organization makes recommendations not only for Europe but also for African countries and other countries with poor social, economic and health development. The proposed approach is relevant only for those regions of Ukraine where cytological examination cannot be carried out. The primary value of this paper is to take into account economic, social, medical situation of each country at the choice of cervical screening strategy.

Recommendations of the American Society of colposcopists and cervical pathologists are of interest; like the WHO recommendations, they were released in 2013 and became the consensus review of the recommendations of 2006 During this period, data of 1.5 million women with dysplasia were analyzed and tracked in the large center in North Carolina according to their cytological material and biopsies.

The American system of screening recommends to begin screening with the 21st year of life. In the age from 21 to 29 years the Liquid-based Cytology (LBC) shall be conducted every three years. LBC provides an opportunity to assess not only the morphology of cells, but also to explore the HPV DNA. In the age group from 30 to 65 years the cytology is supplemented with DNA-typing (“co-testing” in literature) that combines simultaneously cytology and HPV. This examination shall be done every 5 years. LBC is possible only every three years.

Therefore, if a patient has normal cytology, but is infected with HPV, she needs to get into the field of view of the doctor and undergo periodic examinations after six months and a year. And only when the presence of HPV is re-confirmed, further examination can be indicated, because the presence of HPV in such case is the evidence of its persistence.

In practice the diagnosis according to Bethesda classification “Atypical squamous cells of uncertain significance” (the cells that do not exclude the presence of lesions of high degree) is rarely established. However, just this category of patients shows a high probability of the presence of severe and mild forms of dysplasia that require

conductin of colposcopy and biopsy. If colposcopy does not reveal any lesions, co-testing shall be conducted twice with subsequent colposcopy, with an interval of 6 months; anti-inflammatory therapy shall be conducted previously.

During the colposcopy procedure, targeted biopsy and histological examination with the assessment of morphological pattern of CU tissue changes can be carried out. This procedure refers to delayed procedures. Biopsy of CU area with pathological changes is necessary for sampling. For the purpose of diagnostic significance of the procedure, it is necessary to compare two tissue samples. One sample is taken from the CU area with the most pronounced changes, and the other is taken from unchanged area. For sampling, the procedure shall be performed under the control of the colposcope. The sample must include not only epithelium but also stroma.

The WHO Histological Classification (2003)

I. Squamous cell tumours and their predecessors:

1. Unspecified squamous cell carcinoma:
 - a) keratinized;
 - b) non-squamous;
 - c) basaloid;
 - g) verrucous;
 - d) warty;
 - e) papillary;
 - f) lymfoepithelioma;
 - g) papillary squamous transitional cell carcinoma.
2. Microinvasive squamous cell carcinoma.
3. Squamous intraepithelial neoplasia.
4. Squamous cell carcinoma in situ.
5. Benign squamous lesions:
 - a) pointed condyloma;
 - b) squamous cell papilloma;
 - c) fibroepithelial polyp.

II. Glandular cell tumours and their predecessors:

1. Adenocarcinoma:
 - a) mucinous adenocarcinoma:
 - endocervical adenocarcinoma;
 - intestinal adenocarcinoma;
 - ring-shaped cell adenocarcinoma;
 - malignant adenoma;
 - thymic adenocarcinoma.
 - b) endometrioid adenocarcinoma;
 - c) mesonephric adenocarcinoma;
 - d) clear cell adenocarcinoma;
 - e) serous adenocarcinoma.
 2. Microinvasive adenocarcinoma.
 3. Adenocarcinoma in situ.
 4. Dysplasia of glandular epithelium.
- #### III. Other epithelial tumours:
1. Adenosquamous carcinoma:
 - a) vitriform-cell variant.
 2. Adenoid cystic carcinoma.
 3. Adenoid basal carcinoma.
 4. Neuroendocrine tumours:

- a) carcinoid;
- b) atypical carcinoid;
- c) small-cell carcinoma;
- d) large-cell neuroendocrine carcinoma.

5. Undifferentiated carcinoma.

The method of histological examination in the diagnosis of HPV has a high predictive value (90%) but low sensitivity (only 50%). This explains the need to complement histological method of diagnosis of viral infection by PCR. This molecular biological method makes it possible to detect signs of infection before the first clinical manifestations or changes at the cellular level, and with high accuracy identifies a particular type of virus [14]. Also an important phase for the detection of integration of the viral genome with repeated positive results regarding HPV is the detection of cellular biomarkers p16 and Ki67. The presence of both of these markers confirms the proliferation stage that is an irreversible stage of integration of viral DNA into the human genome when spontaneous viral clearance is almost impossible.

In modern conditions this method is the most common. It belongs to amplification diagnostic methods of HPV DNA detection. During a comprehensive examination including histological examination and the use of methods of HPV DNA detection, it is possible to achieve a significant reduction in morbidity and mortality from cervical cancer. In the course of such comprehensive examination it is possible to control the concentration of virus in the body, on the basis of which the conclusion the course and prognosis of the disease can be drawn.

Tactics used in the case of severe forms of lesions are well known and practiced. The only thing the attention shall be paid to, is the patients whose findings reveal atypical glandular cells, adenocarcinoma in situ. These women as well as all women in the ge over 35 years and patients with obesity, oligomenorrhea and abnormal uterine bleeding, in addition to cervical curettage under control of colposcopy shall undergo an endometrial curettage.

The job of a oncogynaecologist includes an important point – the results of the surveys should be correlated: cytology shall confirm the colposcopy, colposcopy shall confirm histology. In cases where such a correlation does not exist, diagnostic conical biopsy is indicated. young women in the age under 24 years are an exception to this, because the risk of the development of invasive cancer is low.

Treatment

Today, the treatment of HPV is performed by different methods, but it is difficult to eliminate the virus from the body. Treatment of HPV diseases at the present stage consists in the elimination of clinical and subclinical manifestations. In each situation the treatment is personalized.

The purpose of treatment of CU pathology is the elimination of the pathological process and the changes in the body that caused its appearance. The principles of treatment are as follows:

- 1) recurrence-free;
- 2) organ-preservation treatment methods in women of reproductive age.

One of the important findings of the latest American recommendations reads as follows: tactics in CINI should be attenuated. It is explained by the research: 60% of mild CIN (dysplasia) regress without any treatment, 32% are unchanged, at 11% show a transition into CINII, 1% is transferred into invasive cancer (Oster A. G.). These data are also applied to HPV-positive women (Syrjanen K. J.).

Treatment of HPV infection in women should be carried out simultaneously in several directions. The purpose of therapy is elimination of the virus from the body, removal of pathological lesions and

recurrence prevention. Most promising is a comprehensive treatment that includes specific antiviral therapy and local effects on altered CU areas.

Given the possible etiopathogenetic mechanisms of proliferative processes in CU, therapy aimed at the elimination of etiological agents through the use of antiviral drugs of direct action and stimulation of own protective resources of the body is essential in the treatment of this disease. Elimination of the causal factor allows the use of attenuated methods of treatment, which is very important because pre-cancer and cervical cancer are most often diagnosed in women of reproductive age, who in the future wish to have children.

In the case of HPV-infection, it is possible to use interferon preparations. In recent years α -, β -, γ -interferon preparations with indirect antiviral, antiproliferative and monomodular action have been used for the treatment of genital human papillomavirus and herpes virus infections (Gomberg M. A. et al. 1998; G. Gross et al., 1998; Syed T. A. et al., 1998; Perry, C. M. et al., 1999; Petersen C. S. et al., 1999; Samgin M. A. et al. 2002; Prilepskaya V. N. et al. 2003).

As for the inductors of endogenous interferon, they have a number of advantages over the interferon preparations (Gomberg M. A. et al. 1998; Ershov F. I. et al. 2005). In the case of papillomavirus and herpesvirus infections of genital organs, interferon preparations increase the content of α -interferon in the blood of patients and have a low monomodular activity; interferon inducers evident exhibited monomodular effect, stimulate the production of α -, β -, γ -interferon, and restore the balance of proinflammatory (interleukin-2, tumor necrosis factor- α) and antiinflammatory (interleukin-10) cytokines [11].

However, complete destruction of the virus by the use of interferons and their inducers is impossible, because the imbalance of cellular immunity at HPV infection is confirmed by such data as the combination of spontaneous regression of hyperplastic manifestations of HPV infection with infiltration of surrounding tissues by lymphocytes and macrophages. Some studies indicate a relation between the HPV clearance from the body with the responses of T-helper cells to S-end domain of viral protein E2.

One of the most promising directions in the treatment and secondary prevention of HPV infection is the use of direct antiviral agents – natural flavonoids (obtained from the mixture of *Herba Deschampsia caespitosa* L. and *Herba Calamagrostis epigeios* L.), which are immunomodulators, activate apoptosis and implement antiproliferative effects on cells. It should be emphasized that due to the ability to directly influence the activity of virus-specific enzymes of DNA- and RNA-polymerases, the use of this group of drugs has a pronounced direct viral static effect on virus of DNA- and RNA-groups, including the human papillomavirus [16-18].

Complex simultaneous systemic and local use of natural flavonoids could be used for the successful treatment of CINI and CINII without surgery [19, 20].

The complex systemic and local application of flavonoids, and interferons in pre- and post- surgery treatment (DEE, cryo- or laser coagulation, radiowave treatment) are undeniably an effective preparation aimed to the reduction of the frequency of relapses [11] and preservation of women's reproductive health.

Local treatment involves removal of the abnormal areas of epithelium by various methods: cryodestruction, radiowave method, laser radiation, or diathermic excision or conization.

Surgery means the removal of affected areas. Mainly used in the presence of large lesions of the tissues in cases of suspected malignancy.

- *Cryosurgery* involves freezing of tumours using liquid nitrogen. The efficiency of this method reaches of 54.8 to 75%. Such relatively low efficiency is a consequence of the viability of the

virus even after its freezing. Cryotherapy is nontoxic, but can cause pain during the “defrosting” of tissues. The side effects may include the possibility of occurrence of blisters and ulcers. When carrying out CU cryotherapy, occasionally deep tissue damage occurs, which can lead to the formation of cicatricial deformity that subsequently manifests in the form of stenosis, atresia of the cervical canal, CU dystonia during childbirth.

- Using *radiowave coagulation* pointed condilomas are eliminated. Radio-wave knife is used in this case. With the help of radiosurgical effects, it is possible to conduct a wide range of CU excisions, and perform LLETZ operations (large loop excision of the transformation zone). The effect of the cut is achieved using the heat generated by the resistance of tissues to the penetration of high frequency radio waves. The last “evaporate” cells directly during the contact with the electrode.

Scalpel and loop electrodes are used for excision, cut and “polishing” of tissues; and ball electrodes are used for coagulation. With the help of radiosurgery method can also be used for CU conization. The most part of surgeries is performed under local anesthesia. The benefits of radiosurgical effects are as follows: rapidity of treatment; no charring, elimination of difficulties during dissection of tissues, no bleeding and pain during surgery. This method of treatment does not cause formation of skin slough and scar tissue, half shortens the period of epithelialization, maintains the architecture of the CU. The effectiveness of radiosurgical treatment is on average from 86 to 90%.

- *Laser radiation* is the elimination of tumors with a laser. This is the only procedure suitable for pregnant women for eliminating condylomas. But the treatment with the help of this procedure does not preclude scarring. Quite effective and safe treatment is the use of laser. The main advantages of CO₂-laser is controlled evaporation of biological tissues without necrosis of neighboring areas, absence of dissemination of tumour cells during surgery and increased resilience of the edges of the laser wound. Among side effects it should be noted the presence of bleeding in the intraoperative period. Healing of laser wounds occurs by primary tension with minimal scarring. The efficiency of lasers in the course of combined therapy of Cu HPV infection is 86-96%. But one of the major drawbacks of laser therapy is the risk of relapse in the presence of transformation zone of 3rd type, because the laser beam does not affect the pathological processes located in the CU channel.
- *Diathermic coagulation* is a method of removing condylomas with radio frequency energy or electro-knife. Diathermic conization is one of the most radical methods for removing lesions. The efficiency is 76, 7–90%. However, increased trauma at intervention, frequent complications (stenosis of the CU canal, endometriosis, damage to the isthmus of the uterus as a result of deep tissue injury, further disorders of reproductive function) limit its use in young women.
- *Hysterectomy*. Indications: • CIN III localized in the cervical canal; in women aged older than 50 years, the technical impossibility of conization in connection with the anatomical features; • the combination of uterine fibroids or ovarian tumours; recurrences after excising treatment. With the spread of the process on vaginal vault the hysterectomy with the excision of upper third of the vagina is indicated.

Follow-up after treatment of benign processes shall be maintained within 3 months, it is recommended to restrict the sexual life and the use of local suppositories containing methyluracil, hyaluronidase or tetrazoles [15].

After treatment of CIN, follow-up continues for up to 2 years.

Postoperative management is of great importance for the final result of surgical treatment. Excision is a common cause of stenosis and other complications. It can be explained by the fact that the phase of healing of the CU is the same as in any other part of the human body. We must understand that after surgery the wound is exposed to infection with anaerobic flora. In the phase of regeneration it is necessary to maintain proliferation.

With the purpose of anti-relapse therapy and promotion of recovery and strengthening the immune system, which is especially important in the fight against HPV infection, it is necessary to indicate drugs with direct antiviral effect (flavonoids).

The important point is the management of CIN during pregnancy. American guidelines and the WHO recommendations emphasize that during pregnancy the treatment is possible for invasive cancer only, so the doctor's task is to eliminate the diagnosis "Invasive cancer."

However, the treatment of women during pregnancy has certain difficulties due to the impossibility of the use of drugs of many classes being banned or not recommended for the use in pregnant women. At the same time, drugs that simultaneously combine direct antiviral action and immunomodulating activity if allowed for use during the period of gestation (natural flavonoids) can not only increase the efficiency of treatment of certain diseases caused by viruses, but also to reduce the frequency of obstetric and perinatal complications of pregnancy in such women.

Possibilities of prevention of cervical cancer by vaccination against HPV

For the prevention of HPV it is necessary to create conditions for the development of specific long-term circulating antibodies against HPV in the human body, it is only possible in the case of vaccination. Primary prevention of cervical cancer consists in carrying out actions

for individuals who do not have signs of the disease, prevent its development in the future. A classic example of primary prevention of cervical cancer is vaccination of adolescent girls prior to sexual activity.

One of the effective methods of fight against HPV is vaccination. Today, two types of vaccines to prevent HPV are used in clinical practice, and recently the third one appeared – nine valent vaccine, the mechanism of action of which is associated with the inclusion of cellular immunity and activation of IgG antibodies [16]. They are made from purified L1 structural proteins that form typespecific for HPV empty shells or viral-like particles (VLPs): HPV-6, HPV-11, HPV-16, HPV-18 – 4 valent vaccine, HPV-16, HPV-18 – duovalent vaccine and HPV-6, HPV-11, HPV-16, HPV-18, HPV-31, HPV-33, HPV-45, HPV-52, HPV-58 – nonavalent vaccine.

Vaccines do not contain live biological products or viral DNA (non-infectious). The HPV vaccine is designed for the prevention of the disease, but not for therapy. It should be noted that the vaccine does not protect against all types of HPV. This means that it will not prevent the development of all cases of cervical cancer or genital condylomas.

About 30% of cases of cervical cancer will not be prevented by vaccination (regular PAP tests shall be conducted) because the vaccine does not affect other oncogenic strains. Also, the vaccine does not prevent about 10% of cases of genital condylomas and does not prevent other sexually transmitted infections.

Secondary prevention of cervical cancer is early detection and treatment of women with precancerous changes in the CU, with the aim of preventing further development of invasive cancer. Tertiary prevention of cervical cancer is a complex or combined treatment, which includes surgery in combination with radiation and chemotherapy on the background of etiotropic therapy.

BIBLIOGRAPHY

1. Human papillomavirus infection // Introduction of HPV vaccines in European Union countries – an update. – 2012.
2. Bruni L., Diaz M., Castellsague X. Cervical Human Papillomavirus Prevalence in 5 Continents: Meta Analysis of 1 Million Women with Normal Cytological Findings // J. Infect.Dis. – 2010. – Vol. 202 (15 December). – P. 1790.
3. Cutts F.T., Franceschi S., Goldie S. Human papillomavirus and HPV vaccines: a review // Bulletin of the World Health Organization. – 2009.
4. Atkinson W., Wolfe S., Hamborsky J. Human Papillomavirus // Epidemiology and Prevention of Vaccine Preventable Diseases [The Pink Book: Course Textbook]. – 12th Edition Second Printing, 2012.
5. Atkinson W., Wolfe S., Hamborsky J. Human Papillomavirus // Epidemiology and Prevention of Vaccine Preventable Diseases. [The Pink Book: Course Textbook]. – 12th Edition Second Printing, 2012.
6. A. Herbert, C. Bergeron, H. Wiener et al. European guidelines for quality assurance in cervical cancer screening: recommendations for cervical cytology terminology. *Cytopathology* 2007: 18: 213–219.
7. M. Arbyn, A. Anttila, J. Jordan et al. European guidelines for quality assurance in cervical cancer screening Second Edition, 2008.
8. Comprehensive Cervical Cancer Control: A guide to essential practice, 2010, World Health Organization, www://whqlibdoc.who.int/publications/2006/9241547006_eng.pdfua=1.
9. European guidelines for quality assurance in cervical cancer screening: recommendations for collecting samples for conventional and liquid based cytology (2007).
10. Berzolla C.E. Dysplasia and malignancy in endocervical polyps / C.E. Berzolla // J Womens Health (Larchmt). – 2007. – Nov. 16 (9). – P. 1317–1321.
11. Jay Naomi. Human papillomavirus infection in women / J. Naomi, Morck Hanna Barbara // Woman and Health (Zhinka i zdorovia). – 2010. – T. 2. – 196.
12. Pathology of the cervix and uterus: guidelines for doctors of obstetrics, oncology, cytologists, histologists, educators and students of medicine / ed. E.V. Kohanevich. – Nizhyn: Hidromaks, 2009. – 350 C.
13. Timuss E., Adams K. The cervix. *Cytological Atlas* / E. Timuss Adams K., translated from English, ed. by N. I. Kondrikova. – M.: Practical medicine, 2009. – 251 p.
14. Danilova N. V. Tumors of the cervix. Morphological diagnostics and genetics: Guidelines for physicians / N. V. Danilova, Yu. Yu. Andreeva, L. E. Zavalishina T. V. Kekeeva, P. G. Malkov, G. A. Frank; ed. Yu. Yu. Andreeva, G. A. Frank. – M.: Practical medicine, 2012. – 116 p.
15. Voloshina N. N., Voloshin N.. Screening and prevention of cervical cancer. – Zaporozhye: Pechatny Mir, 2010. – 155 p.
16. Voitenko G. N., Kokhanov S.V. Pharmacoeconomic rationale for the use of drug proteflazid in the treatment of human papillomavirus infection // "Recept". – 2016. – Vol. 19, No. 3.
17. Zaporozhan V.N., Marichereda V.G., Dimcheva L.I. The use of flavonovy glycosides in the therapy of genital human papillomavirus infection in women // Application of flavonivyh glycosides papilomavirusnoy therapy of genital infection in women. *Journal of Health Sciences*. 2014; 4 (12) : 93–104. ISSN 1429 9623 / 2300 665X.
18. Peculiarities of pregnancy and delivery in women with multiple pregnancy / B. M. Ventskivski, I. V. Poladych, V. V. Bila, A. Yu. Kostenko, K. S. Kazydub // *Medicine of transport of Ukraine*. – 2015. – No. 3-4. – S. 8-15.
19. Ventskovsky B. Proteflazid® in the treatment and prevention of human herpesvirus infection in pregnant women: a meta analysis of clinical trials results / B. Ventskovsky, O. Grynevych, MD, V. Mikhailov, M. Lesnikova, L. Yaschenko, T. Broun // *American Journal of Science and Technologies*. – 2016. – № 1 (21). – January June. – P. 983–1002.
20. Godlevskaya N.. The efficiency of systemic and local riy ца drug Proteflazid in the treatment of diseases of the cervix caused by HPV infection / N.A. Godlevskaya, A. V. Starovir // *Zdorovie zhenshchiny*. – 2012. – № 3 (69). – P. 80–83.
21. Godlevskaya N.A. Clinical efficacy of local application of vaginal suppositories Proteflazid® in the treatment of cervical intraepithelial neoplasia of mild to moderate degree caused by human papillomavirus / N.A. Godlevskaya, A. V. Starovir // *Zdorovie Zhenshchiny*. – 2017. – № 2 (118). –S. 55-60.